

## Case Report: Cystoscopic Use of Cyanoacrylate Glue for Bleeding during Transurethral Resection of Bladder Tumors

LUCA CARMIGNANI, M.D., PIETRO ACQUATI, M.D., and FRANCESCO ROCCO, M.D.

### ABSTRACT

An 81-year-old woman with a history of nephroureterectomy and bladder cuff excision for grade 3 stage pT<sub>3</sub>N<sub>0</sub>M<sub>0</sub> transitional-cell neoplasia presented with three bladder neoplasms. She also had symptomatic varicose veins in the lower extremities and received low-molecular-weight heparin. During transurethral resection of the tumors, deep ablation of the base of one lesion resulted in significant arterial bleeding that could not be controlled with normal endoscopic techniques. On the basis of previous positive experience, we endoscopically injected 3 mL of cyanoacrylate glue (Glubran 2) deeply (5 mm) into the tissue surrounding the bleeding site, making four injections with a device used for collagen injections. The area was irrigated with mannitol and sorbitol, and within a few seconds, there was complete remission of bleeding. We waited a further 90 seconds with the bladder distended to allow the substance to lose its adhesive properties so as to avoid having the bladder walls stick together. The catheter was removed on the third day, with resumption of micturition and clear urine. This appears to be the first case of cystoscopic use of cyanoacrylate glue to control bleeding.

### INTRODUCTION

**S**URGICAL CONVERSION of a transurethral resection of a bladder tumor (TURBT) for urinary bladder cancer is extremely rare. Endoscopic revision of a TURBT after eschar shedding or for sudden bleeding may be more frequent, particularly in subjects undergoing anticoagulant therapy. The use of glues has become increasingly widespread in recent years: they are currently used in the treatment of caliceal fistulas,<sup>1</sup> in nephrotomy,<sup>2</sup> for the treatment of aneurysms<sup>3</sup> and arteriovenous fistulas,<sup>4</sup> and in other fields such as for ligation of esophageal varices.<sup>5</sup> We report the first case of which we are aware of the use of cyanoacrylate glue (Glubran 2) in cystoscopy for post-TURBT bleeding.

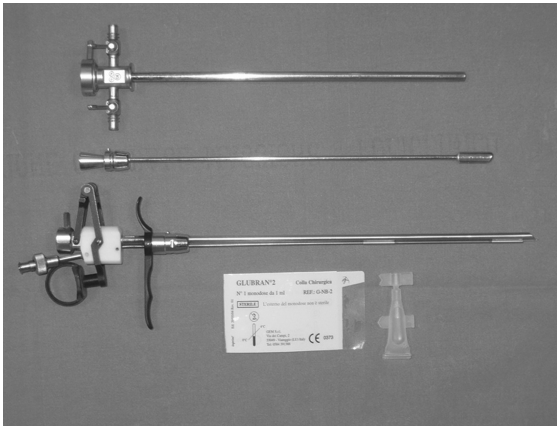
### CASE REPORT

An 81-year-old woman weighing 60 kg presented with three bladder neoplasms diagnosed during routine cystoscopy. The woman had undergone surgery 6 months before with nephroureterectomy and bladder cuff excision for grade 3 stage pT<sub>3</sub>N<sub>0</sub>M<sub>0</sub> transitional-cell neoplasia. The largest of the bladder neoplasms was about 2 cm and was situated at the site of the

scar of the previous bladder cuff. We decided to stage the tumors and if possible perform TURBT. The patient also had symptomatic varicose veins in the lower extremities and received low-molecular-weight heparin (nadroparin) 3800 IU from the day preceding surgery and on the day of surgery.

During TURBT, the bladder lesions were removed, and deep ablation of the base of the lesion was performed for staging purposes at the site of the previous papillary tumor. This resulted in significant arterial bleeding that could not be controlled with normal endoscopic techniques (diathermic loop with coagulant, spray coagulation). It was not possible to attempt coagulation by using a holmium laser because the machine was temporarily unavailable.

After several attempts to achieve coagulation, we were considering the possibility of converting the procedure to open surgery. Instead, on the basis of previous positive experience using glue to achieve hemostasis in open surgery, we endoscopically injected 3 mL of cyanoacrylate glue (Glubran 2) deeply (5 mm) into the tissue surrounding the bleeding site, making four injections with a device used for collagen injections (21F Storz 5° cystoscope with a 19-gauge needle) (Fig. 1). The area was irrigated with mannitol and sorbitol, commonly used for endoscopic resections. Within a few seconds, there was complete remission of bleeding. We then waited a further 90



**FIG. 1.** Cystoscopic instruments used included 19-gauge collagen-injection device and Glubran 2 cyanoacrylate glue.

seconds with the bladder distended, to allow the substance to lose its adhesive properties so as to avoid having the bladder walls stick together. The patient was catheterized, and the lavage fluid remained clear. In the following days, an ultrasound scan revealed a hyperechoic area at the injection site. The catheter was removed on the third day, with resumption of micturition and clear urine. Histologic examination showed a transitional-cell carcinoma pT<sub>1</sub> grade 2. Cystoscopy at 3 months was negative.

## DISCUSSION

We have described here the first cystoscopic use of cyanoacrylate glue to control bleeding. In this specific case, the bleeding probably was from a branch of the uterine artery or a large bladder vessel, and it also is possible that the use of an anticoagulant contributed to the difficulty we encountered in achieving the hemostasis.

Cyanoacrylate is commonly used to control hemorrhage arising from ruptured esophageal varices, and its mechanism of action is polymerization in an exothermic reaction when it comes into contact with a fluid or a basic medium. Recently, it has found widespread use in urology in the correction of caliceal fistulas,<sup>1</sup> in nephrotomy,<sup>2</sup> in the correction of arteriovenous fistulas,<sup>3</sup> chyluria,<sup>6</sup> erectile dysfunction secondary to veno-occlusive dysfunction,<sup>7</sup> and cystotomy repair.<sup>8</sup> No endoscopic use has been described previously. We thought the presence of lavage fluid would limit this use, but the TURBT irrigation solution did not cause any problems when the cyanoacrylate was injected laterally into the bleeding area of the muscular wall and perivesical tissue. Rare cases of complications related to the use of this drug in huge doses and close to the lung area have been reported in the literature.<sup>9</sup> However, no toxicity or carcinogenicity has been ascribed to this substance.<sup>10</sup> The instrument set used for the injection is in common use in urology units for collagen injections. The high

cost of these glues could be offset by the absence of catheterization.

It must be mentioned that cystoscopic application is not among the recommended usages of cyanoacrylate, and this could raise legal issues. The case described here is particularly unusual, as it is rare to be unable to achieve endoscopic hemostasis. Bleeding in the ample inner resection margins or unstable hemostasis, particularly in strongly anticoagulated patients or in transurethral prostatic resections with particularly heavy bleeding, are much more frequent occurrences. In these cases, this simple procedure could aid hemostasis and reduce catheterization and hospitalization time.

## REFERENCES

1. Tekin MI, Peskircioglu L, Boyvat F, Ozkardes H. Practical approach to terminate urinary extravasation: Percutaneous fistula tract embolization with N-butyl-cyanoacrylate in a case with partial nephrectomy. *Techn Urol* 2001;7:67.
2. Sofer M, Greenstein A, Chen J, Nadu A, Kaver I, Matzkin H. Immediate closure of nephrostomy tube wounds using tissue adhesive: A novel approach following percutaneous endourological procedures. *J Urol* 2003;169:2034.
3. Suzuki Y, Nakada T, Ishigooka M, et al: Pelvic arteriovenous aneurysm caused by transurethral resection of the prostate: Successful management by intra-arterial embolization. *Urol Int* 1998;60:191.
4. Cekirge S, Oguzkurt L, Saatci I, Boyvat F, Balkanci F. Embolization of a highoutput postnephrectomy aortocaval fistula with Gianturco coils and cyanoacrylate. *Cardiovasc Intervent Radiol* 1996;19:56.
5. Dhiman RK, Chawla Y, Taneja S, Biswas R, Sharma TR, Dilawari JB. Endoscopic sclerotherapy of gastric variceal bleeding with N-butyl-2-cyanoacrylate. *J Clin Gastroenterol* 2002;35:222.
6. Tuck J, Pearce I, Pantelides M. Chyluria after radical nephrectomy treated with N-butyl-2-cyanoacrylate. *J Urol* 2000;164:778.
7. Peekircioflu L, Tekin I, Boyvat F, Karabulut A, Özkardee H. Embolization of the deep dorsal vein in the treatment of erectile impotence due to veno-occlusive dysfunction. *J Urol* 2000;163:472.
8. Seifman BD, Rubin MA, Williams AL, Wolf JS Jr. Use of absorbable cyanoacrylate glue to repair an open cystotomy. *J Urol* 2002;167:1872.
9. Van Beek AP, van Erpecum KJ. Fatal N-butyl-2-cyanoacrylate pulmonary embolism after sclerotherapy for variceal bleeding. *Endoscopy* 2005;37:687.
10. Hwang SS, Kim HH, Park SH, et al. N-butyl-2-cyanoacrylate pulmonary embolism after endoscopic injection sclerotherapy for gastric variceal bleeding. *J Comput Assist Tomogr* 2001;25:16.

Address reprint requests to:  
Luca Carmignani, M.D.  
Via Luigi Sacco 7  
Milan 20100, Italy

E-mail: luca.carmignani@unimi.it

## ABBREVIATION USED

TURBT = transurethral resection of bladder tumor.